

# Pathogenesis of *Eimeria praecox* in chickens: virulence of field strains compared with laboratory strains of *E. praecox* and *Eimeria acervulina*

R. B. Williams<sup>1</sup>, R. N. Marshall<sup>2</sup>, M. Pagès<sup>3\*</sup>, Martina Dardi<sup>3</sup> and E. del Cacho<sup>4</sup>

<sup>1</sup>Coxitec Consulting, Hertfordshire, UK, <sup>2</sup>Veterinary Laboratories Agency (Weybridge), New Haw, Addlestone, Surrey KT15 3NB, UK, <sup>3</sup>Laboratorios Hipra, Avenida la Selva 135, 17170 Amer (Girona), Spain, and <sup>4</sup>Department of Animal Pathology, Faculty of Veterinary Sciences, University of Zaragoza, Spain

The pathogenesis in chickens of the apicomplexan *Eimeria praecox* was compared with that of *Eimeria acervulina*, using intestinal lesions, mucosal integrity, body weight gain (BWG) and the feed conversion ratio (FCR) as criteria. Characteristics of each species were described by combinations of polymerase chain reaction assays and classic parasitological signs. There were considerable overlaps in lengths, breadths, shape indices and volumes of the oocysts of each species. Both species caused statistically significant reductions in BWG at the lowest inocula tested (500,000 sporulated oocysts per bird of *E. praecox* and 250,000 of *E. acervulina*). *E. praecox* was observed for the first time to cause actual body weight loss and marked increases in FCR, as did *E. acervulina*. *E. acervulina* caused gross, white pathognomonic lesions, but *E. praecox* caused micro-lesions, visible in fresh tissue only with a dissecting microscope. Occasionally, lesions of the Houghton strain of *E. acervulina* were observed to be rounded, rather than typically “ladder-like”. Both species caused villous erosion and atrophy. No mortality occurred in birds receiving up to 1 million sporulated oocysts of either species. Using BWG and FCR as criteria, the virulence of recent field strains of *E. praecox* from Wales (Tynyngogl) and the USA (Raleigh) was compared with English laboratory strains of *E. praecox* (Houghton) and *E. acervulina* (Houghton). *E. praecox* (Tynyngogl) was markedly more virulent than *E. acervulina* (Houghton), which was more virulent than *E. praecox* (Raleigh) and *E. praecox* (Houghton).

## Introduction

The apicomplexan genus *Eimeria* comprises at least 1160 species that parasitize vertebrate animals (Levine, 1988). Those found in farm animals cause serious financial losses worldwide, with poultry perhaps being the worst affected. In chickens, *Eimeria acervulina*, *Eimeria brunetti*, *Eimeria maxima*, *Eimeria mitis*, *Eimeria necatrix*, *Eimeria praecox* and *Eimeria tenella* each causes a separately recognizable disease resulting from the fundamental differences among the pathogenic effects characteristic of each species.

Although often used synonymously, the terms pathogenicity (characteristic capacity to cause disease, and its course of development) and virulence (degree of pathogenicity) should be clearly distinguished (Williams, 2006). Whilst the characteristic pathogenicity of each particular species is a constant feature, virulence may be regarded as an intraspecific variation. Thus the inherent virulence of any strain (as opposed to the pathogenicity of a species) may be greatly influenced by exogenous factors. In the present study, the size of parasite inoculum and the breed, age and diet of the host were consistent throughout.

There has been continuing controversy over the pathogenesis and virulence of *E. praecox* in relation to other *Eimeria* species in the chicken, with particular

regard to the necessity of their inclusion in live vaccines (Williams, 2002). However, there seem to have been no studies published on field strain variation in *E. praecox*, and there is little on its clinical effects, namely Long (1967a, 1968), Oikawa & Kawaguchi (1976), Gore & Long (1982), Salisch (1990), Jorgensen *et al.* (1997), Williams (1998, 2001), Williams & Catchpole (2000), Jenkins *et al.* (2008), in contrast with hundreds of papers on *E. acervulina*. Therefore, the present study was carried out to confirm the specific pathogenic effects of *E. praecox* and to investigate the difference in virulence of recent field strains from Europe and the USA. Comparisons were made with standard laboratory strains of *E. praecox* and *E. acervulina*. *E. acervulina* was chosen for comparison with *E. praecox* because of its similar development site in the intestine and because it is generally accepted as being capable of causing serious disease, whereas *E. praecox* is often considered to be relatively innocuous.

## Materials and Methods

**Provenance of parasites.** The strains of *E. praecox* and *E. acervulina* used were named and characterized as far as possible according to the

\*To whom correspondence should be addressed. E-mail: mpb@hipra.com

Received 9 January 2009

ISSN 0307-9457 (print)/ISSN 1465-3338 (online)/09/50359-08 © 2009 British Crown Copyright

DOI: 10.1080/03079450903186028

recommendations and terminology of Joyner *et al.* (1978). They were as follows:

1. *E. praecox* (H): the Houghton strain, previously described by Shirley *et al.* (1984). The line used was kindly provided by E. del Cacho, University of Zaragoza, Spain, who initially obtained it from J. Catchpole, Veterinary Laboratories Agency (VLA), Weybridge, UK in 2001, since when it had been maintained in liquid nitrogen.
2. *E. praecox* (T): the Tynyongl strain, isolated at the VLA for the present study from an oocyst sample collected from a broiler flock near Tynyongl, Wales, in January 2007. The strain was established from this sample by collecting the earliest oocysts produced from the first passage, then further multiplying them by *in vivo* passage in chickens at the VLA.
3. *E. praecox* (R): the Raleigh strain, isolated at the Laboratorios Hipra from an oocyst sample collected from a broiler flock near Raleigh, North Carolina, USA, in February 2005, and kindly supplied by M. Jenkins (USDA, Beltsville, USA). The strain was established from the stock derived from this sample by a passage initiated by a single oocyst, and maintained since then frozen in liquid nitrogen.
4. *E. acervulina* (H): the Houghton strain (Long, 1967b). The line used was established at the Laboratorios Hipra from a stock kindly provided by J. H. Morgan (Institute of Animal Health, Compton, UK) in 2001, and maintained since then frozen in liquid nitrogen.

**Characterization of parasites.** Characteristics of each species were described by a combination of polymerase chain reaction (PCR) assays and classic parasitological signs. This part of the work was carried out at the Laboratorios Hipra (Amer, Spain).

**DNA analyses.** The identity of each *Eimeria* species was confirmed by PCR before use in the *in vivo* experiments. Clean suspensions of sporulated oocysts were prepared, and the oocyst walls were then disrupted by grinding each sample with a mini-pestle in a 1.5-ml Eppendorf tube (Haug *et al.*, 2007). DNA was extracted from homogenates using a commercial kit according to the manufacturer's instructions (DNeasy; Qiagen). Identification of species was carried out using published methods for PCR assays of species-specific ITS-1 sequences of *rDNA*. Primers, sequences and methodologies for *E. praecox* and *E. acervulina* are presented in Table 1. PCR assays with positive and negative controls were also carried out on each strain of *E. praecox* and *E. acervulina* with specific primers for *E. tenella*, *E. brunetti*, *E. necatrix*, *E. mitis* and *E. maxima*. No bands corresponding to those species occurred in any of the resulting gels. All assays were carried out separately, since diagnostic multiplex PCR systems are less sensitive and less reproducible than simplex systems (Haug *et al.*, 2007). In general, the assays could detect <100 oocysts; or <10 for *E. acervulina* and *E. tenella*. Every PCR assay was carried out at least three times to confirm reproducibility of the results.

**Parasitological methods.** The PCR results were corroborated (detailed results not shown here) by classic parasitological methods following infection of birds with 500,000 sporulated oocysts of all three *E. praecox* strains, or 250,000 sporulated oocysts of *E. acervulina* (H). In all cases endogenous parasites were seen in the duodenum and upper part of the jejunum, but nowhere else in the intestine, 4 to 6 days after infection. In the case of *E. acervulina* (H), pathognomonic lesions were observed in the duodenum and upper jejunum. No gross discrete lesions were seen for *E. praecox* strains, but the intestinal wall was thickened and the

duodenum had mucoid contents. Oocyst measurements were also carried out on each strain (see below).

**Oocyst measurements, shapes and volumes.** Freshly sporulated oocysts of each strain of each species, suspended in 2.5% w/v potassium dichromate, were measured at random. An Olympus CX31 microscope with an Olympus Altra 20 camera attachment was used, computer-controlled by an Olympus Analysis getIT program to take the photographs and an Olympus CellID program to measure the oocysts. The time between placing a cover slip over a drop of oocyst suspension on a microscope slide and taking the necessary multiple photographs was less than 3 min in order to avoid distortion of oocysts by evaporation of the suspension medium. By observing the position of the sporocysts in an oocyst, it was ensured that each oocyst was correctly orientated before it was measured. Photographs of several fields were taken randomly at  $\times 200$  magnification until images of about 80 oocysts were obtained, from which the length and breadth of each oocyst were derived. Each oocyst length was related to the breadth of the same oocyst, so that individual shape indices and volumes could be calculated validly. The shape index of each oocyst was calculated as: length/breadth. The approximate volume of each oocyst was calculated as that of an ellipsoid:  $4/3 \times \pi \times (\text{length}/2) \times (\text{breadth}/2)^2$ .

**Experimental design of main study.** The *in vivo* experimental work was carried out at the VLA. Replicate groups of 10 chicks were infected (except the uninfected controls, which received sterile distilled water as a sham infection) with *E. praecox* ( $1 \times 10^6$  or  $0.5 \times 10^6$  oocysts) at 14 days of age (day 0) or with *E. acervulina* ( $1 \times 10^6$ ,  $0.5 \times 10^6$ , or  $0.25 \times 10^6$  oocysts) on day 2. Duplicate groups infected with *E. praecox* were individually weighed on each of days 0 to 7 and 14, whilst duplicate groups infected with *E. acervulina* were similarly weighed on days 2 to 9 and 16. The daily weights of the uninfected controls were obtained on the same days as the *E. praecox*-infected birds, and, being 2 days out of synchrony with *E. acervulina*-infected birds, were adjusted to provide the control data for the *E. acervulina* infections, estimated from mean daily weight gains. Having carried out the adjustment of the uninfected controls for *E. acervulina*, the results from *E. acervulina*-infected birds were expressed for the same time periods as those from the *E. praecox*-infected birds.

The total feed consumed during days 0 to 7, days 7 to 14 and days 0 to 14 by each cage of 10 birds was weighed, and the feed conversion ratios (FCRs) were calculated by dividing the weight of feed consumed by the total body weight gain (BWG) of the birds in the same cage during the same time period. FCRs of the uninfected controls for *E. acervulina* were estimated from the feed consumption data from the uninfected controls for *E. praecox*, adjusted in a way similar to that for BWGs.

Clinical signs and mortality for every cage of birds were recorded on each of days 0 to 14 after infection. The intestines of all of the 10 birds in each of two further cages per treatment were examined for lesions and mucosal integrity; the birds in one cage were killed 4.5 days after infection (for *E. praecox*) or 5 days after infection (for *E. acervulina*), and those in the remaining cage for each species were killed on day 14.

**Chickens and husbandry.** Specific-pathogen-free chicken eggs (SPAFAS) were hatched in a specific-pathogen-free incubator. The newly hatched chicks were reared coccidia-free in a strictly controlled isolation building. They were accommodated in large wire-floored cages, and given access to feed and water *ad libitum*. The feed was the standard VLA formula (CDG Shipston), milled on premises where no anticoccidial drugs are employed. The feed contains wheat (42%), maize (25%), soya (20%) and fish meal (10%); protein 23% and energy 12.76 MJ/kg.

**Table 1.** Species-specific primers and methods for PCR assays of *E. praecox* and *E. acervulina* used in the present study

Primer name	Sequence (5' to 3')	Species	Methodology
E.p.F	CAT CAT CGG AAT GGC TTT TTG A	<i>E. praecox</i>	Schnitzler <i>et al.</i> (1999)
E.p.R	AAT AAA TAG CGC AAA ATT AAG CA	<i>E. praecox</i>	Schnitzler <i>et al.</i> (1999)
E.a.F	GGC TTG GAT GAT GTT TGC TG	<i>E. acervulina</i>	Schnitzler <i>et al.</i> (1998)
E.a.R	CGA ACG CAA TAA CAC ACG CT	<i>E. acervulina</i>	Schnitzler <i>et al.</i> (1998)

At 14 days of age (day 0) the mixed-sex birds were wing-tagged, weighed, randomized and allocated to 40 groups of 10 chicks each, in wire-floored cages (1 m<sup>2</sup> floor area) in another disinfected building, where they were inoculated. Heating was by forced, filtered air with an average temperature of approximately 21°C, and the daily lighting programme was 23 h followed by 1 h of darkness. Animal welfare and experimental treatments were compliant with the prevailing UK legislation. All birds were inspected at least once a day by an animal technician, and also periodically by laboratory staff.

**Administration of parasites.** Chicks were infected by gavage with sporulated oocysts of *E. praecox* on day 0 or of *E. acervulina* on day 2. Infective material of each parasite was less than 1 week old when inoculated. To confirm accurate dosing, each bulked inoculum was weighed before and after administration, and the weight dispensed was calculated and compared with the weight expected to have been used for the number of birds infected. None of the weights dispensed deviated by more than 1.7% from that expected for any inoculum.

**Lesion scoring and mucosal integrity.** Birds were killed by injection into a brachial vein of approximately 0.2 ml pentobarbitone ("Solution 20% for Euthanasia"; J. M. Loverage, Southampton, UK), this being the method of choice for avoiding spontaneous disruption of intestinal epithelium during euthanasia (Rose *et al.*, 1975). Gross coccidial lesions due to *E. acervulina* were assessed immediately after death, and were graded according to the scoring system of Johnson & Reid (1970), with a potential range of scores 0 to 4. Since *E. praecox* does not cause consistently recognizable macroscopic lesions, such a system is not appropriate for that species; hence an unpublished scoring system (Laboratorios Hipra) was used for *E. praecox*, with a potential range of grades of 0 to 2. Grade 0 indicates normal intestine and contents; Grade 1 indicates a normal intestinal wall with no thickening, but with some liquid contents in the mid-gut zone, and perhaps even more liquid in the duodenum; and Grade 2 indicates a slightly thickened and wrinkled duodenal wall, with marked whitish mucoid and liquid duodenal contents, and undigested food in the caudal small intestine. This scoring system grades the gut condition, rather than coccidial lesions, resulting from an *E. praecox* infection; it is not comparable with the scoring of *E. acervulina* lesions.

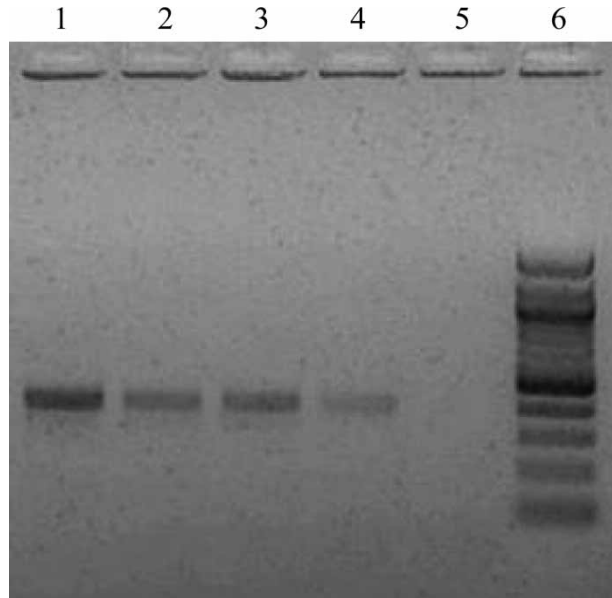
After lesion scoring, some segments of gut were excised from selected birds for closer examination of the mucosal integrity under physiological saline with a dissecting microscope (Williams, 2005). Some samples of mucoid gut contents adhering to those segments were then transferred with a needle-point onto a glass slide for examination with a Nikon Eclipse 50i microscope. Photographs were obtained through both microscopes with a Nikon E4500 Coolpix digital camera.

**Statistical analyses.** Oocyst dimensions, daily body weights, BWGs and FCRs were analysed by analysis of variance, followed by Tukey's Honestly Significant Difference (HSD) test where appropriate. The experimental unit for BWGs and FCRs was a cage. Before analysis, oocyst dimensions were transformed to log<sub>10</sub> then back-transformed after analysis.

## Results

**Characterization of parasites. DNA analyses and parasitological observations.** Simplex PCR assays confirmed the identities of the *E. praecox* and *E. acervulina* strains previously determined by classic parasitological characteristics. Furthermore, combinations of PCR assays and parasitological methods did not reveal contamination of any strains with *E. tenella*, *E. brunetti*, *E. necatrix*, *E. mitis* or *E. maxima* (gels not shown). The confirmatory PCR assays for diagnosis and purity of each strain were all reproducible. Figure 1 illustrates the specific identity of the three strains of *E. praecox* used in this study.

**Oocyst measurements, shapes and volumes.** Oocyst measurements and derived dimensions are presented in



**Figure 1.** PCR assay gel confirming specific identification of *E. praecox* strains used in this study. Lane 1, *E. praecox* (Houghton); lane 2, *E. praecox* (Tynyngongl); lane 3, *E. praecox* (Raleigh); lane 4, positive control ("Hipracox Broilers", a vaccine that includes *E. praecox*); lane 5, negative control; lane 6, DNA marker (100 base pair ladder; Qiagen).

Table 2. The mean lengths of all the *E. praecox* strains are statistically significantly greater than those of *E. acervulina* (H). However, the lengths of all the *E. praecox* strains also differ significantly from each other. The breadths of *E. praecox* (R) and *E. praecox* (H) are similar, but both are smaller than *E. praecox* (T). The mean breadths of all the *E. praecox* strains are greater than that of *E. acervulina* (H). The shape index of *E. acervulina* (H) is greater than that of all the *E. praecox* strains, but those of *E. praecox* (R) and *E. praecox* (H) are different from each other (unlike in the case of their breadths), although both are similar to *E. praecox* (T). *E. acervulina* (H) has a significantly smaller volume than any of the *E. praecox* strains, but *E. praecox* (T) has a significantly greater volume than either *E. praecox* (R) or *E. praecox* (H).

In summary, there are statistically significant differences between all of the parameters of *E. acervulina* and *E. praecox* oocysts, but there are also differences among those of the *E. praecox* strains. It is notable that *E. praecox* (R) and *E. praecox* (H) oocysts have closely similar volumes, but significantly different shapes. Furthermore, the shape index of *E. praecox* (R) oocysts approaches that of *E. acervulina* (H), although they are statistically significantly different. In all the strains of *E. praecox* and *E. acervulina*, subspherical oocysts with shape indices of 1.01 or 1.02 are not uncommon. Figures 2a to 2d illustrate the range of sizes and shapes of oocysts in the inocula used here (not the same samples as were used for measuring the oocysts at the Laboratorios Hipra).

**Clinical effects. Lesion scores and mucosal integrity.** All uninfected control birds had normal intestines and gut contents. The scores for gut condition of all birds given each inoculum of *E. praecox* were maximal (score 2) at 4.5 days post infection (d.p.i.). Mean scores of *E. praecox* groups at 14 d.p.i. were 0.5 to 0.65. Mean

**Table 2.** Means and extremes of oocyst dimensions of *Eimeria* strains used in the present study (n = 80)

Species and strain	Mean length × breadth (µm)	Shape index	Volume (µm <sup>3</sup> )
<i>E. praecox</i> (Houghton) (observed extremes)	20.48 ± 1.78 <sup>B</sup> × 17.59 ± 1.47 <sup>B</sup> (16.62 to 24.94 × 14.96 to 21.11)	1.16 ± 0.08 <sup>A</sup> (1.02 to 1.37)	3374 ± 811 <sup>B</sup> (1947 to 5687)
<i>E. praecox</i> (Tynyongl) (observed extremes)	22.69 ± 2.08 <sup>D</sup> × 19.24 ± 2.35 <sup>C</sup> (18.54 to 27.77 × 15.03 to 24.61)	1.18 ± 0.10 <sup>AB</sup> (1.02 to 1.63)	4539 ± 1535 <sup>C</sup> (2464 to 8667)
<i>E. praecox</i> (Raleigh) (observed extremes)	21.71 ± 2.12 <sup>C</sup> × 17.89 ± 1.74 <sup>B</sup> (16.86 to 26.59 × 14.73 to 22.53)	1.21 ± 0.11 <sup>B</sup> (1.01 to 1.53)	3720 ± 1040 <sup>B</sup> (2154 to 6940)
<i>E. acervulina</i> (Houghton) (observed extremes)	18.20 ± 1.45 <sup>A</sup> × 14.45 ± 1.06 <sup>A</sup> (14.78 to 22.02 × 11.72 to 16.67)	1.26 ± 0.10 <sup>C</sup> (1.02 to 1.55)	2011 ± 387 <sup>A</sup> (1089 to 3046)

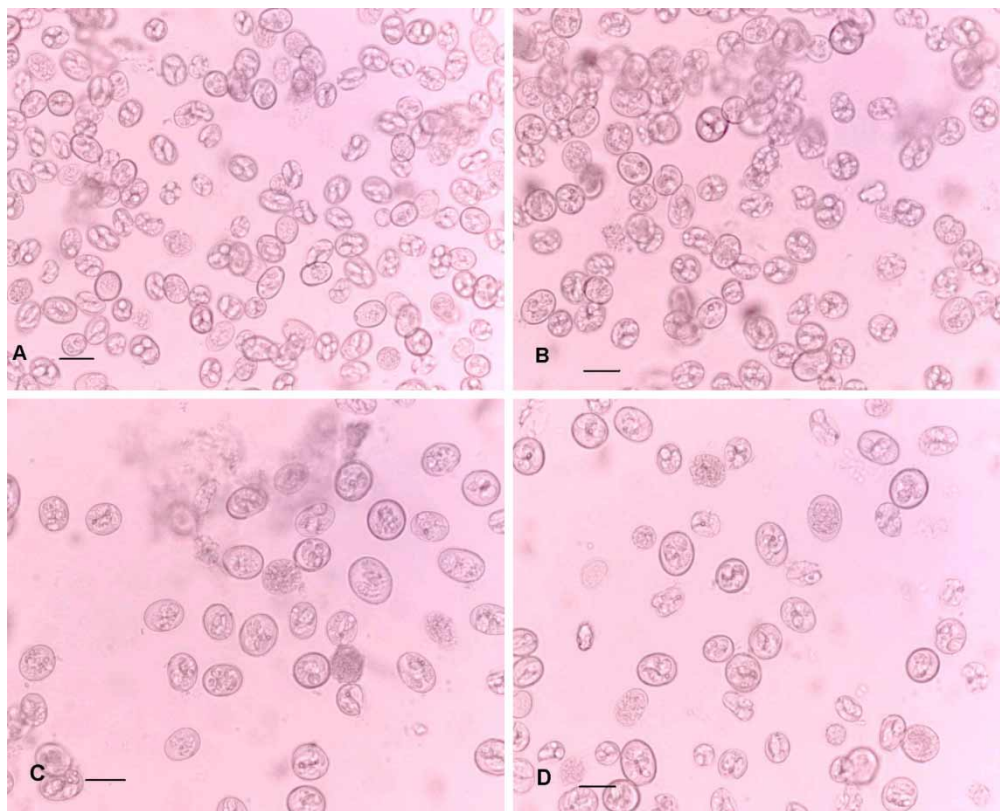
Data presented as mean ± standard deviation. Values in each column with different upper case superscript letters are statistically significantly different at  $P \leq 0.05$  by Tukey's HSD test.

gross lesion scores for *E. acervulina* groups were relatively low, being only 1.0 to 1.1 at 5 d.p.i., very few birds having lesions scored as 2 or 3. No birds infected with *E. acervulina* had lesions after 14 days. There were no clearly dose-related differences within any strain or species. The many *E. praecox* results with a standard deviation of zero and the scarcity of lesions due to *E. acervulina* rendered statistical analysis inappropriate.

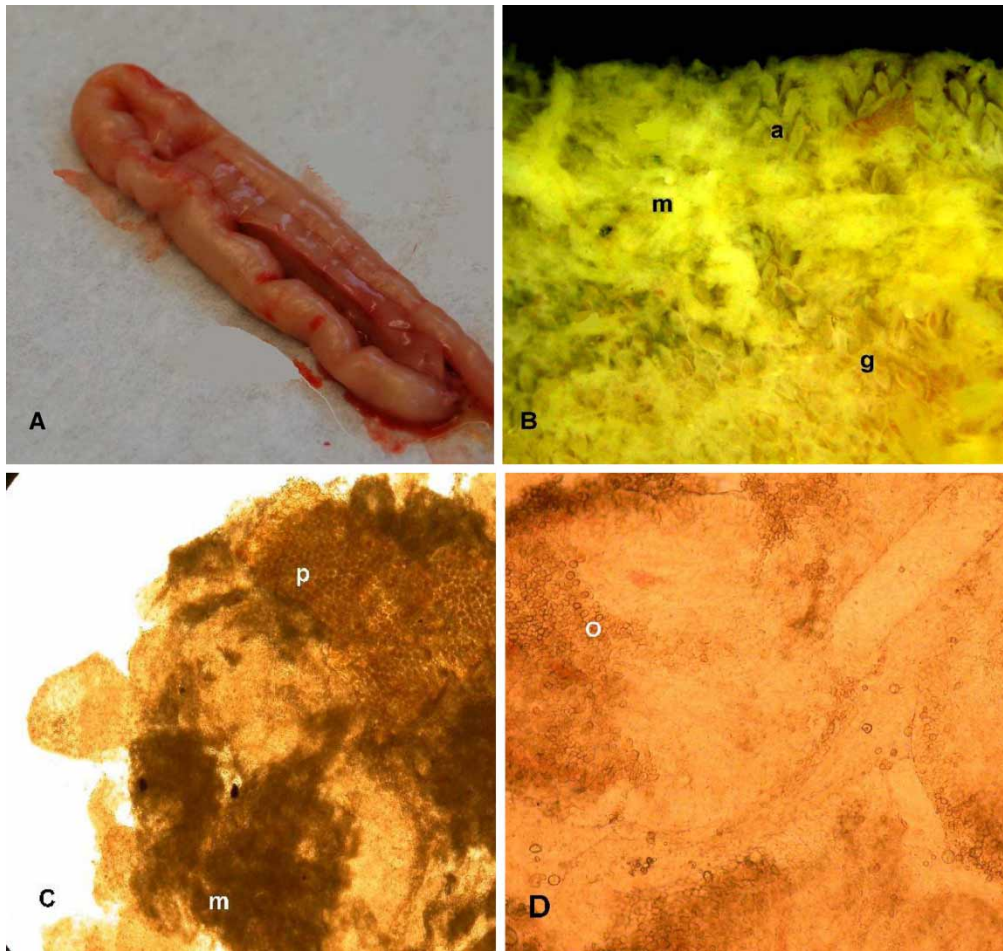
Palpation and naked-eye examination of unopened intestines 4.5 d.p.i. with  $1 \times 10^6$  or  $0.5 \times 10^6$  oocysts of *E. praecox* revealed thickened walls with a somewhat wrinkled appearance (Figure 3a). On opening the gut, the contents were somewhat liquid, with varying degrees of viscosity. The Tynyongl strain appeared to cause more mucoid contents than did the Houghton and Raleigh strains. The colours of the gut contents were quite variable, even for the same strain. The higher dose of the Houghton and Tynyongl strains induced a homogeneous greyish mucus, whilst the mucus resulting from

the Raleigh strain at the same dose was greyish with yellowish flecks. At the lower dose, the Houghton strain induced greyish mucus, but the Tynyongl strain induced stringy, yellowish mucus. The mucus induced by the Raleigh strain was greyish in some birds and yellowish in others. The intestines of most birds appeared normal 14 d.p.i., whichever strain of *E. praecox* they had received.

Direct examination of the mucosa with a dissecting microscope showed that in birds infected with *E. praecox* a greyish mucoid exudate occurred in veil-like patches. Beneath those patches, the villi were severely eroded, leaving "ghosts" of the villar coria (Figure 3b); but where exudate was absent, complete villi remained, although often atrophied in comparison with villi of uninfected birds. The additional flecks of cream-coloured to yellow viscous material frequently present in areas of erosion were smeared onto a microscope slide and examined with a high-power objective. The material consisted of a mixture of minute particles of plant matter, viscous mucus



**Figure 2.** The relative sizes and shapes of the oocysts in the inocula used for experimental infections. 2a: *E. acervulina* (Houghton). 2b: *E. praecox* (Houghton). 2c: *E. praecox* (Raleigh). 2d: *E. praecox* (Tynyongl). Scale bars = 20 µm.



**Figure 3.** 3a: Unopened duodenum of bird infected with  $10^6$  sporulated oocysts of *E. praecox* (Tynyong1) showing wrinkled appearance. 3b: Duodenal mucosa under saline of bird infected with  $10^6$  sporulated oocysts of *E. praecox* (Tynyong1), showing mucus veil (m), atrophied villi (a), and "ghosts" (g) of the coria of eroded villi. 3c: Smear of duodenal contents from bird infected with  $0.5 \times 10^6$  sporulated oocysts of *E. praecox* (Houghton), showing plant material (p), patches of mucus (m), and fragmented villi. 3d: Smear of duodenal mucosa of bird infected with  $0.5 \times 10^6$  sporulated oocysts of *E. praecox* (Tynyong1), showing fragmented villi containing oocysts (o).

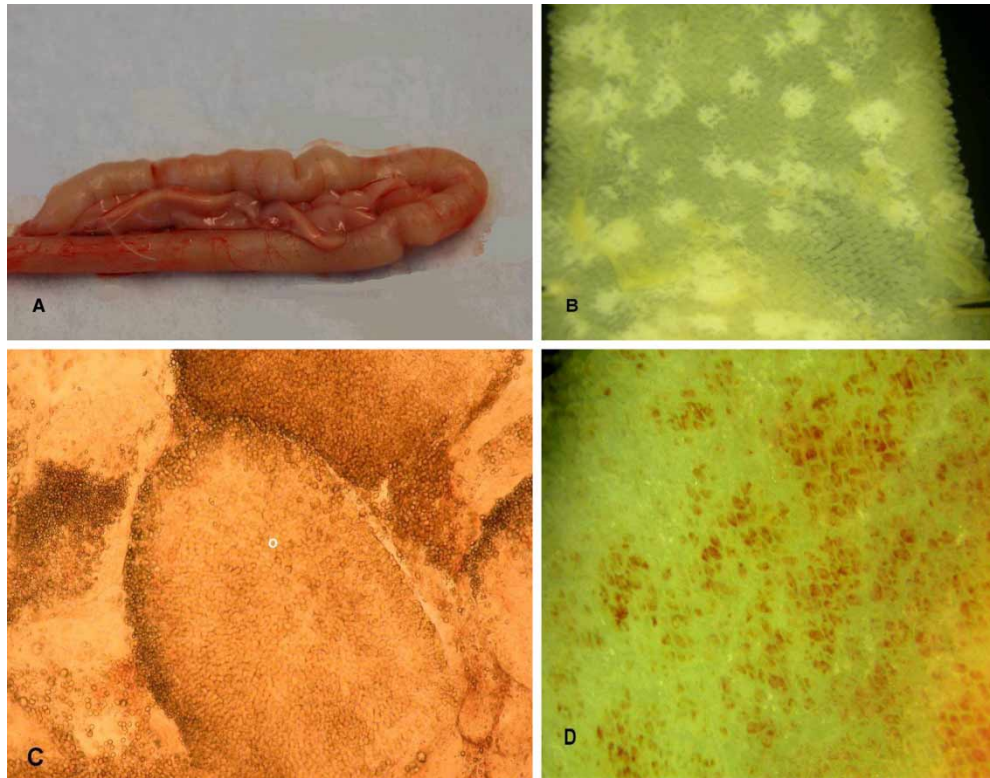
and detached pieces of villi loaded fairly uniformly with parasites (gametocytes and oocysts) (Figures 3c and 3d). Sometimes, material of similar gross appearance was also seen in uninfected birds, but it was much less viscous, and contained only plant matter and rather less mucus.

Five d.p.i. with  $1 \times 10^6$  or  $0.5 \times 10^6$  oocysts of *E. acervulina* (H), palpation and naked-eye examination of unopened intestines revealed rather thickened walls with a somewhat wrinkled appearance (Figure 4a). The wrinkling was noticeably less in birds infected with  $0.25 \times 10^6$  oocysts. In all cases, the opened guts contained slightly viscous liquid occasionally tinged with green (probably bile) and the mucosa was sometimes congested. The intestines of most birds appeared normal 14 d.p.i., however many oocysts they had received.

When examined with a dissecting microscope, the villi of birds infected with *E. acervulina* were seen to be reduced in height compared with those of uninfected birds. The discrete, whitish, pathognomonic lesions were sometimes transversely orientated across the gut, but were often more or less rounded (Figure 4b). The healthy-looking villi surrounding the lesions could be gently moved aside with a needle-point without causing damage; but when a lesion was directly prodded, the white area disintegrated into a mass of loose tissue and mucus, demonstrating its fragility. In an individual villus, a white

area was seen to be concentrated in the mucosa of the tip of the spatulate villus in a horseshoe shape. When examining material from disintegrated lesions with a high-power objective, the mucosa of the villus tips was packed with mature oocysts (Figure 4c), in contrast to the usually more uniform distribution of *E. praecox* parasites along the villi. Very heavy infections completely stripped off the mucosa from the muscularis mucosae, leaving large areas of inflammation and the "ghosts" of the villar coria (Figure 4d). Parts of the intestine so affected exhibited no discrete gross lesions, showing only uniform pale pinkish serosal and mucosal surfaces.

**Weight gains.** The mean daily body weights of birds infected with different doses of each *E. praecox* strain were lower than the uninfected controls from 3 to 4 d.p.i. until 14 d.p.i. These body weight differences were, however, statistically significant ( $P \leq 0.05$ ) only in the cases of *E. praecox* (T) (both doses until day 14) and *E. praecox* (R) ( $1 \times 10^6$  oocysts per bird until day 7; and  $0.5 \times 10^6$  oocysts per bird until day 6). All doses of *E. acervulina* (H) caused statistically significantly lower ( $P \leq 0.05$ ) mean body weights than those of uninfected controls, beginning between 3 and 4 d.p.i., and continuing until 14 d.p.i. Most notably, with both doses of *E. praecox* (T), there was an actual loss of body weight



**Figure 4.** 4a: Unopened duodenum of bird infected with  $10^6$  sporulated oocysts of *E. acervulina* (Houghton) showing wrinkled appearance. 4b: Jejunal mucosa under saline of bird infected with  $0.25 \times 10^6$  sporulated oocysts of *E. acervulina* (Houghton) showing rounded lesions. 4c: Smear of duodenal mucosa of bird infected with  $10^6$  sporulated oocysts of *E. acervulina* (Houghton), showing villi containing oocysts (o). 4d: Muscularis mucosae of the duodenum, under saline, of bird infected with  $10^6$  sporulated oocysts of *E. acervulina* (Houghton), showing inflammation, and "ghosts" of the coria of the stripped-off villi.

from 3 d.p.i. until at least 6 or 7 d.p.i. In the case of *E. acervulina* (H), body weight loss occurred with all doses from 3 d.p.i., but it persisted only until 6 d.p.i. and was generally less than half as great as that caused by *E. praecox* (T).

Table 3 presents the mean BWGs of birds during different periods up to 14 d.p.i. Preliminary analyses of covariance indicated no statistically significant effects of initial bird weights (day 0) on their BWGs (days 0 to 7,  $P = 0.506$ ; days 7 to 14,  $P = 0.313$ ; days 0 to 14,  $P = 0.318$ ). Therefore, comparisons of treatment groups were carried out by one-way analysis of variance for each

species for each time period. During the acute phase (days 0 to 7), the mean BWGs of all infected birds were less than those of the uninfected controls for each species, but only *E. praecox* (T) (both doses) and *E. acervulina* (H) (all doses) produced statistically significant reductions in BWG. During days 7 to 14, there were no statistically significant differences between any treatments within each species. Overall (days 0 to 14), only *E. praecox* (T) (both doses) and *E. acervulina* (H) (all doses) caused statistically significantly lower BWGs than those of the respective uninfected controls. During days 0 to 7 and 0 to 14, the mean BWGs of birds

**Table 3.** Mean body weight gain for three time periods after infection: each species analysed separately

Inoculum	Mean BWG (g) and as percentage of appropriate control		
	Days 0 to 7	Days 7 to 14	Days 0 to 14
Water ( <i>E. praecox</i> control)	72.1 (100%) <sup>C</sup>	91.7 (100%) <sup>A</sup>	163.9 (100%) <sup>C</sup>
<i>E. praecox</i> (H) $1 \times 10^6$	66.3 (92%) <sup>C</sup>	89.0 (97%) <sup>A</sup>	155.3 (95%) <sup>C</sup>
<i>E. praecox</i> (H) $0.5 \times 10^6$	65.5 (91%) <sup>C</sup>	86.7 (94%) <sup>A</sup>	151.9 (93%) <sup>C</sup>
<i>E. praecox</i> (T) $1 \times 10^6$	15.9 (22%) <sup>A</sup>	82.4 (90%) <sup>A</sup>	98.3 (60%) <sup>A</sup>
<i>E. praecox</i> (T) $0.5 \times 10^6$	32.5 (45%) <sup>B</sup>	85.1 (93%) <sup>A</sup>	117.6 (72%) <sup>AB</sup>
<i>E. praecox</i> (R) $1 \times 10^6$	59.1 (82%) <sup>C</sup>	87.2 (95%) <sup>A</sup>	146.2 (89%) <sup>C</sup>
<i>E. praecox</i> (R) $0.5 \times 10^6$	57.5 (80%) <sup>C</sup>	86.1 (94%) <sup>A</sup>	143.6 (88%) <sup>BC</sup>
Water ( <i>E. acervulina</i> control)	78.6 (100%) <sup>b</sup>	93.6 (100%) <sup>a</sup>	172.3 (100%) <sup>b</sup>
<i>E. acervulina</i> (H) $1 \times 10^6$	33.6 (43%) <sup>a</sup>	88.5 (95%) <sup>a</sup>	122.1 (71%) <sup>a</sup>
<i>E. acervulina</i> (H) $0.5 \times 10^6$	37.3 (47%) <sup>a</sup>	87.1 (93%) <sup>a</sup>	124.4 (72%) <sup>a</sup>
<i>E. acervulina</i> (H) $0.25 \times 10^6$	49.4 (63%) <sup>a</sup>	90.5 (97%) <sup>a</sup>	139.9 (81%) <sup>a</sup>

Values in each column with different superscript letters are statistically significantly different at  $P \leq 0.05$  by Tukey's HSD test. Upper case and lower case superscripts to be treated separately. Values in the final column do not always equal the total of the other two columns because of rounded-off figures.

infected with either dose of *E. praecox* (T), as percentages of uninfected controls, were lower than those of birds infected with the corresponding doses of *E. acervulina* (H).

**Feed conversion ratios.** Table 4 presents the mean FCRs of infected and uninfected birds during different periods up to 14 d.p.i. Despite some quite large numerical differences between the FCRs during the period of acute disease (days 0 to 7), most were not statistically significant, because of the inherent variability among the duplicate cages of birds. Nevertheless, the two higher doses of *E. acervulina* produced FCRs about 2.4 to 2.6 times greater than those of the controls, which is as expected from the BWG results. Only the higher dose of *E. praecox* (T) produced a statistically significantly greater FCR than that of the control birds, but all the remaining *E. praecox* inocula resulted in numerically greater FCRs than the controls. There were no statistically significant differences between FCRs of any treatments during the recovery period (days 7 to 14) or overall.

## Discussion

Despite a common but mistaken notion that *E. praecox* is practically innocuous, its effect is clinically similar to that of *E. acervulina*, which is generally accepted to be damaging to commercial chickens. The reported variability in the effects of either species may often result from differences in the numbers of oocysts administered or other exogenous factors, but may also reflect differences in strain virulence. Therefore, in the present study various infective doses of laboratory and field strains of *E. praecox* from different continents were compared with a laboratory strain of *E. acervulina* as a standard, under identical conditions. The objective was to demonstrate the pathogenesis of *E. praecox* in comparison with *E. acervulina* and to elucidate any possible differences in strain virulence for *E. praecox*.

The infective doses employed of both *E. praecox* and *E. acervulina* caused adverse effects on BWG and FCR. The inocula of  $0.5 \times 10^6$  and  $1 \times 10^6$  sporulated oocysts of *E. praecox* (T) reduced BWG by 55% and 78%,

**Table 4.** Mean feed conversion ratios for three time periods after infection: each species analysed separately

Inoculum	Mean FCR		
	Days 0 to 7	Days 7 to 14	Days 0 to 14
Water ( <i>E. praecox</i> control)	2.396 <sup>A</sup>	2.899 <sup>A</sup>	2.678 <sup>A</sup>
<i>E. praecox</i> (H) $1 \times 10^6$	2.789 <sup>A</sup>	3.871 <sup>A</sup>	3.386 <sup>A</sup>
<i>E. praecox</i> (H) $0.5 \times 10^6$	3.713 <sup>AB</sup>	3.199 <sup>A</sup>	3.424 <sup>A</sup>
<i>E. praecox</i> (T) $1 \times 10^6$	9.570 <sup>B</sup>	3.886 <sup>A</sup>	4.763 <sup>A</sup>
<i>E. praecox</i> (T) $0.5 \times 10^6$	4.996 <sup>AB</sup>	4.364 <sup>A</sup>	4.538 <sup>A</sup>
<i>E. praecox</i> (R) $1 \times 10^6$	3.715 <sup>AB</sup>	3.747 <sup>A</sup>	3.734 <sup>A</sup>
<i>E. praecox</i> (R) $0.5 \times 10^6$	4.922 <sup>AB</sup>	4.258 <sup>A</sup>	4.532 <sup>A</sup>
Water ( <i>E. acervulina</i> control)	2.545 <sup>a</sup>	2.838 <sup>a</sup>	2.706 <sup>a</sup>
<i>E. acervulina</i> (H) $1 \times 10^6$	6.164 <sup>a</sup>	3.893 <sup>a</sup>	4.503 <sup>a</sup>
<i>E. acervulina</i> (H) $0.5 \times 10^6$	6.658 <sup>a</sup>	3.907 <sup>a</sup>	4.715 <sup>a</sup>
<i>E. acervulina</i> (H) $0.25 \times 10^6$	3.588 <sup>a</sup>	3.105 <sup>a</sup>	3.272 <sup>a</sup>

Values in each column with different superscripts are statistically significantly different at  $P \leq 0.05$  by Tukey's HSD test. Upper case and lower case superscripts to be treated separately.

respectively, during 1 week—far exceeding the greatest reductions (20 to 25%) previously recorded (Long, 1968; Gore & Long, 1982; Williams, 1998; Williams & Catchpole, 2000). Similar inocula increased FCRs by 55% (H), 105% (R) or 300% (T), exceeding the greatest previously recorded increases of 4 to 29% (Williams & Catchpole, 2000).

Regarding *E. acervulina* (H), BWG reductions of up to 57% occurred during 1 week after infection, which fall into the expected range of 4 to 64% reduction caused by about  $0.5$  to  $1.0 \times 10^6$  oocysts (Hein, 1968; Long, 1968; Reid & Johnson, 1970; Michael & Hodges, 1971; Williams, 1998, 2006; Williams & Catchpole, 2000). An increase in FCR of 162% occurred after infection with  $0.5 \times 10^6$  oocysts, greatly exceeding the 1 to 34% increases with a similar inoculum recorded by Williams & Catchpole (2000) and Williams (2006).

No birds infected with either species died, but *E. acervulina* produced gross pathognomonic lesions, whilst *E. praecox* caused only microscopic lesions associated with reductions in viscosity of gut contents. The pathogenic effects in the gut due to *E. praecox* were all maximal during the acute phase and persisted, although much reduced, 14 days after infection. This contrasted with the gross lesions of *E. acervulina*, which were rather milder than expected during the acute phase, possibly because they were scored a few hours too early for maximal effects to be discernible. No gross *E. acervulina* lesions were visible 14 days after infection.

It is important to note that considerable variation in the form of the intestinal lesions in birds infected with *E. acervulina* was observed in this study. Thus, in the widely-used Houghton strain, lesions may be rounded (see Figure 4b) as well as "ladder-like" (as they are almost invariably described). Edgar & Seibold (1964) considered such rounded lesions to be caused by their newly described nominal species *E. mivati* in contrast to the typical transverse *E. acervulina* lesions.

The combined methods used here to characterize the parasites are particularly effective for accurate species identification. Thus, the PCR assays supported the identification of each species based upon pathogenic effects in chickens, and as a result the amplicon sizes of the gel bands can now be correlated with the classic parasitological characteristics of each species. This increases confidence in the conclusion that *E. acervulina* is the species responsible for the rounded white lesions that are sometimes found in the duodenum and jejunum of chickens. We are not aware of any previous publications in which PCR assays are correlated with classic parasitological characteristics of *Eimeria* species.

To assess differences in virulence of the *E. praecox* strains, bird growth was regarded as the primary criterion. There were clear differences between the effects on BWG during the acute phase of infection. The Tynyongl strain was the most virulent, followed by the Raleigh and Houghton strains. In comparison with *E. acervulina* (H), which caused 37 to 57% BWG reductions ( $P < 0.05$ ), *E. praecox* (T) was more virulent, whilst the Raleigh and Houghton strains were less virulent.

In previous studies, heavy primary infections of *E. acervulina* usually caused body weight loss in young chicks (Hein, 1968; Long, 1968; Williams, 1998), but similar infections in older birds sometimes only reduced daily BWGs (Long, 1968). In contrast, *E. praecox* has hitherto been found only to reduce daily BWGs (Oikawa

& Kawaguchi, 1976; Gore & Long, 1982; Shirley *et al.*, 1984; Williams, 1998), as did the Houghton and Raleigh strains in the present study. Hence, our findings with the Tynyongl strain apparently constitute the first demonstration that *E. praecox* can cause actual body weight loss in chicks, as *E. acervulina* may do. *E. praecox* (T) also caused a significant increase in FCR.

Volume is the most meaningful measure of oocyst size. Morphometric results confirmed that *E. acervulina* oocysts are significantly smaller than *E. praecox* oocysts, but there was considerable overlap between all the dimensions measured, both between species and among the *E. praecox* strains. The means of the shape indices of the *E. praecox* strains were similar to each other but were significantly different from those of *E. acervulina*. However, the observed extremes within the data sets of all strains of both species completely overlapped. In this study, the shape index of individual oocysts therefore proved to be an extremely unreliable species identifier, particularly as all strains of both species contained subspherical oocysts. Despite the convenience of the shape index, which is suggestive in species identification, volume remains the most reliable measurable characteristic of oocysts.

The present study has demonstrated that laboratory and field strains of *E. praecox* may exhibit a much wider range of virulence than previously thought. Furthermore, the virulence of *E. praecox* may not only equal but may exceed that of *E. acervulina*. Incidentally, important variation in the form of *E. acervulina* lesions has been observed and considerable overlaps in oocyst dimensions and shape indices of *E. praecox* and *E. acervulina* have been demonstrated.

### Acknowledgements

The authors thank Robin Sayers (VLA) for carrying out the statistical analyses, and Jeremy H. Morgan (Institute of Animal Health, Compton, UK) and Mark Jenkins (USDA, Beltsville, USA) for providing samples of oocysts. Skilled technical assistance was provided at the VLA by Jackie A. Marshall, Michael Haslam and Margaret Newlands; and at Laboratorios Hipra, by Natalia Dewe, Natalia Bello and Noelia Lopez.

### References

- Edgar, S.A. & Seibold, C.T. (1964). A new coccidium of chickens, *Eimeria mivati* sp. n. (Protozoa: Eimeriidae) with details of its life history. *Journal of Parasitology*, *50*, 193–204.
- Gore, T.C. & Long, P.L. (1982). The biology and pathogenicity of a recent field isolate of *Eimeria praecox* Johnson, 1930. *Journal of Protozoology*, *29*, 82–85.
- Haug, A., Thebo, P. & Mattson, J.G. (2007). A simplified protocol for molecular identification of *Eimeria* species in field samples. *Veterinary Parasitology*, *146*, 35–45.
- Hein, H. (1968). The pathogenic effects of *Eimeria acervulina* in young chicks. *Experimental Parasitology*, *22*, 1–11.
- Jenkins, M., Allen, P., Wilkins, G., Klopp, S. & Miska, K. (2008). *Eimeria praecox* infection ameliorates effects of *Eimeria maxima* infection in chickens. *Veterinary Parasitology*, *155*, 10–14.
- Johnson, J. & Reid, W.M. (1970). Anticoccidial drugs: lesion scoring techniques in battery and floor-pen experiments with chickens. *Experimental Parasitology*, *28*, 30–36.
- Jorgensen, W.K., Stewart, N.P., Jeston, P.J., Molloy, J.B., Blight, G.W. & Dalgliesh, R.J. (1997). Isolation and pathogenicity of Australian strains of *Eimeria praecox* and *Eimeria mitis*. *Australian Veterinary Journal*, *75*, 592–595.
- Joyner, L.P., Canning, E.U., Long, P.L., Rollinson, D. & Williams, R.B. (1978). A suggested terminology for populations of coccidia (Eimeriorina), particularly of the genus *Eimeria* (Protozoa: Apicomplexa). *Parasitology*, *77*, 27–31.
- Levine, N.D. (1988). *The Protozoan Phylum Apicomplexa*. Boca Raton, FL: CRC Press, Inc.
- Long, P.L. (1967a). Studies on *Eimeria praecox* Johnson, 1930, in the chicken. *Parasitology*, *57*, 351–361.
- Long, P.L. (1967b). Studies on *Eimeria mivati* in chickens and a comparison with *Eimeria acervulina*. *Journal of Comparative Pathology and Therapeutics*, *77*, 315–325.
- Long, P.L. (1968). The pathogenic effects of *Eimeria praecox* and *E. acervulina* in the chicken. *Parasitology*, *58*, 691–700.
- Michael, E. & Hodges, R.D. (1971). The pathogenic effects of *Eimeria acervulina*: a comparison of single and repeated infections. *The Veterinary Record*, *89*, 329–333.
- Oikawa, H. & Kawaguchi, H. (1976). Effect of mode of infection on manifestation of symptom and oocyst production in chicken coccidiosis. IV. *Eimeria praecox* and *E. mitis*. *Japanese Journal of Parasitology*, *25*, 141–147. [In Japanese]
- Reid, W.M. & Johnson, J. (1970). Pathogenicity of *Eimeria acervulina* in light and heavy coccidial infections. *Avian Diseases*, *14*, 166–171.
- Rose, M.E., Long, P.L. & Bradley, J.W.A. (1975). Immune responses to infections with coccidia in chickens: gut hypersensitivity. *Parasitology*, *71*, 357–368.
- Salisch, H. (1990). A study of the life cycle of *Eimeria praecox*, Johnson 1930. *Journal of Veterinary Medicine B*, *37*, 363–368.
- Schnitzler, B.E., Thebo, P., Mattsson, J.G., Tomley, F.M. & Shirley, M.W. (1998). Development of a diagnostic PCR assay for the detection and discrimination of four pathogenic *Eimeria* species of the chicken. *Avian Pathology*, *27*, 490–497.
- Schnitzler, B.E., Thebo, P., Tomley, F.M., Uggla, A. & Shirley, M.W. (1999). PCR identification of chicken *Eimeria*: a simplified read-out. *Avian Pathology*, *28*, 89–93.
- Shirley, M.W., McDonald, V., Chapman, H.D. & Millard, B.J. (1984). *Eimeria praecox*: selection and characteristics of precocious lines. *Avian Pathology*, *13*, 669–682.
- Williams, R.B. (1998). Epidemiological aspects of the use of live anticoccidial vaccines for chickens. *International Journal for Parasitology*, *28*, 1089–1098.
- Williams, R.B. (2001). Quantification of the crowding effect during infections with the seven *Eimeria* species of the domesticated fowl: its importance for experimental designs and the production of oocyst stocks. *International Journal for Parasitology*, *31*, 1056–1069.
- Williams, R.B. (2002). Anticoccidial vaccines for broiler chickens: pathways to success. *Avian Pathology*, *31*, 317–353.
- Williams, R.B. (2005). Direct assessment of physical gut integrity by mucosal examination. *World Poultry*, *21*(10), 43–45.
- Williams, R.B. (2006). Relative virulences of a drug-resistant and a drug-sensitive strain of *Eimeria acervulina*, a coccidium of chickens. *Veterinary Parasitology*, *135*, 15–23.
- Williams, R.B. & Catchpole, C. (2000). A new protocol for a challenge test to assess the efficacy of live anticoccidial vaccines for chickens. *Vaccine*, *18*, 1178–1185.